

Contrast Sensitivity Function (CSF): The Neglected Vision Test

BY STUART RICHER, OD, PHD, FAAO

Audiologists do not evaluate a single sound frequency when prescribing hearing aids to their patients. Rather, monaural and binaural audiograms more fully express the results of a hearing test, in terms of how well their patients hear sounds of broad frequencies (high, medium, and low pitch) and loudness (intensity). Presbycusis is similar to presbyopia and represents high frequency hearing loss, typically age-related. Significantly, the entire audiometric curve or function depicts the type, degree, and configuration of hearing loss.¹

Eyecare practitioners (ECP) measure visual acuity, a single parameter of vision known as 'resolution.' This is the ability of an optical system (or a patient) to 'resolve' high spatial frequency symbols, typically high-contrast Snellen letters. For the majority of ECPs, this type of testing has not changed since the mid-19th century, even with the advent of digital projection screens. The reason has much to do with efficiently prescribing eyeglasses. Only with the advent of contact lenses and refractive and cataract surgery

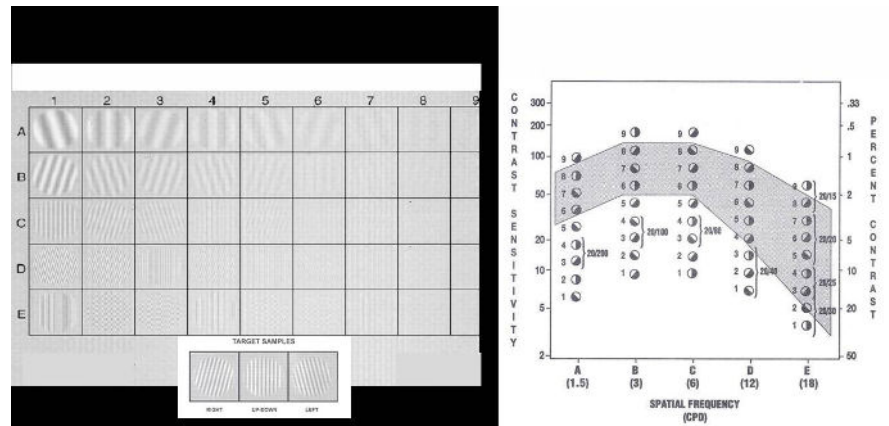


FIGURE 1: THE STEREO OPTICAL FVA MEASURES CONTRAST SENSITIVITY BY GENERATING A CSF CURVE THAT PORTRAYS SENSITIVITY ON THE Y-AXIS AND SPATIAL FREQUENCY ON THE X-AXIS.

has the measurement of contrast sensitivity function (CSF) gained traction among ECPs.

The Stereo Optical Functional Vision Analyzer (FVA) is the gold standard for measuring contrast sensitivity by generating a CSF curve that portrays sensitivity on the y-axis and spatial frequency on the x-axis, following a subjective forced-choice testing paradigm repeated nine times at each of five spatial frequencies (**Figure 1**).

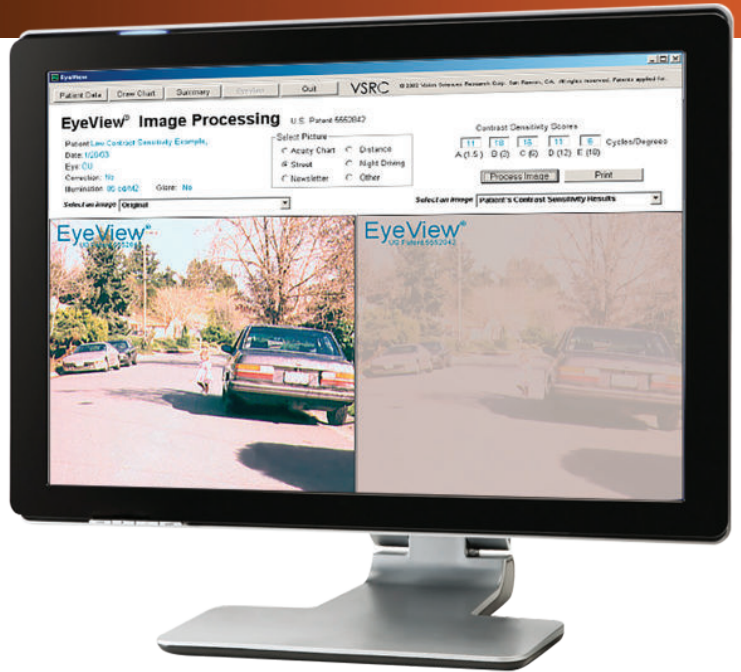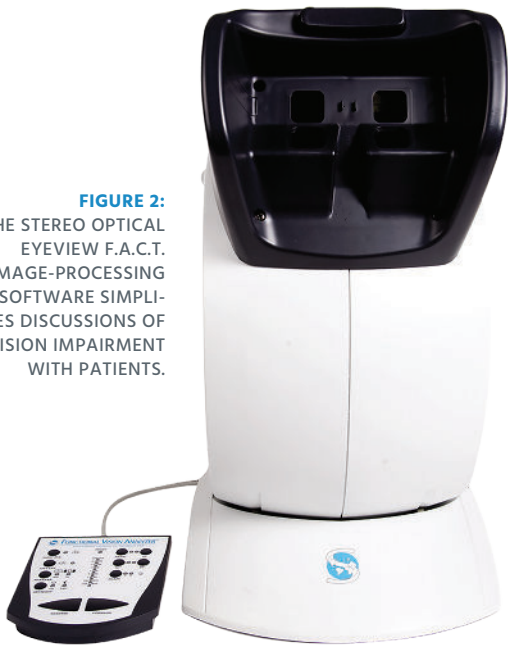
The Functional Acuity Contrast Test (F.A.C.T.) within FVA depicts CSF under monocular, binocular, photopic (85 cd/m²), and mesopic (3 cd/m²) conditions with and without the

choice of two glare conditions (high/low) and five spatial frequencies (1.5, 3, 6, 12, and 18 cycles per degree).

Four points are important:

1. The visual system is most sensitive to lower spatial frequencies of approximately six cycles per degree or gratings equivalent to the size of 20/100 letters.
2. The visual system is least sensitive to gratings of high spatial frequency, which is the reason high-contrast letters are used to test vision.
3. All spatial frequencies define image quality, analogous to an audiogram.

FIGURE 2:
THE STEREO OPTICAL
EYEVIEW F.A.C.T.
IMAGE-PROCESSING
SOFTWARE SIMPLIFIES
DISCUSSIONS OF
VISION IMPAIRMENT
WITH PATIENTS.



4. Full CSF output or visual capacity as 'area under the curve' composite scoring is possible.

Beyond viewing raw CSF data graphically, ECPs can use the Stereo Optical EyeView F.A.C.T. image-processing software to simplify discussions of vision impairment with patients and their families. This is accomplished by digitally simulating the way the impaired eye sees a photographic scene before and after ophthalmologic medical or surgical intervention (**Figure 2**).

FVA is the standard in research in industry and pharmaceutical evaluation primarily because of the accumulated age-related normative data available. In addition, evaluations of CSF have been shown to help ECPs in clinical settings.

Enhancing Clinical Judgement

These are the areas of increasing occurrence within practices that ECPs should pay attention to in

order to enhance their diagnostic acumen, educate patients, build a thriving enterprise, and move vision testing into the modern era. Contrast sensitivity function changes are often observed in most patients, despite stable visual acuity and stable fundus photography appearance.

Contact Lenses and Premium IOL Fields

In the contact lenses field and premium IOL field, the decision to use a premium lens is assisted by determining CSF under conditions with or without glare. Choice of the optical zone diameter can impact the degree of glare disability buttressed by FVA data. For instance, one group assessed and compared the effects of four simultaneous-image multifocal contact lenses and those with distant-vision-only contact lenses on visual performance in early presbyopes, under dim conditions, including the effects of induced glare.²

Cataract Co-Management

Clinical research has demonstrated that continuous CSF decline with age results from increasing spherical aberration of the human crystalline lens. Replacing the crystalline lens with a pseudophakic lens can provide superior visual acuity, as well as contrast sensitivity and functional vision. As advances in the technology allow cataract and refractive surgeons to address higher-order optical aberrations, the measurement of functional vision becomes increasingly critical as a gauge of the progress in primary and secondary post-surgical cataracts.³

A cataract might rapidly interfere with activities of daily living, such as driving a car or reading small print even with the finest spectacle correction. All too often, the patient, optometrist and surgeon have trouble defining and documenting the quality of vision loss beyond visual acuity. In such cases, FVA provides crucial data on visual impairment with and

without glare. These two factors—loss of CSF and glare disability—intersect with the ability to safely drive an automobile, particularly under stressed conditions of low contrast and high glare, such as night driving with and without rain, fog, and snow, and compounded by disease.

Contrast sensitivity testing is assuming a prominent place in medical and surgical evaluations because it reflects functional vision, correlates with visual performance, and provides a key to understanding optical and visual processing of images. Some practices take full advantage of the enhanced capability of FVA to comprehensively evaluate the driving vision, using a protocol that encompasses peripheral vision assessment, day vs. night luminance, color vision, and detection of traffic signs.

Age-Related Macular Degeneration and Diabetes

Age-related macular degeneration (AMD), whether exudative or the much more common atrophic variety, presents another challenge for ECPs and their patients, in terms of an actual description of the functional vision loss. Indeed, it has been shown that most ECPs underestimate the impact AMD carries on ambulation and mental health, mainly because visual acuity is preserved until much of the structure of the retina has been compromised. That is, the retina can thin out parafoveally, with little impact on visual acuity.⁴ Even a time-efficient measure of mesopic—high glare CSF at six cycles per degree, as

employed in the CREST study would be a welcome addition to the typical eye exam.⁵

Data-rich advances now allow clinical descriptions of layer-by-layer anatomical tissue disruption within the retina—RPE interface—vascular



The ability to supply rich granular data on the visual system is finally moving beyond the halls of research.

interface. SD-OCT, SD-OCT-A, and swept-source imaging typically lacks a widely employed visual correlation beyond visual acuity. Although dark adaptometry, macula pigment optical density, and three-channel anomaloscope color vision are notable exceptions, all fail to describe the functional vision loss patients actually are experiencing. As with cataract, the effect of glare adds another real-life dimension to the doctor's assessment and patients' appreciation of their functional ability compared with similarly aged patients.

Data from our lab suggests that CSF can be improved with prescriptive carotenoid xanthophyll supplements (lutein and/or zeaxanthin).⁶ More revealing is a publication suggesting that measuring six cycles per degree peak CSF under the mesopic lighting condition plus glare is an effective measure of retinal function

vs. dysfunction in AMD patients that can be supported with carotenoid supplementation.⁷ What's more, macular pigment optical density, resulting CSF and driving vision can all be enhanced with changes in diet and nutritional supplementation.⁸

Recently, early functional contrast sensitivity impairment and nonvisible structural neuroretinal changes have been found in diabetic retinopathy as the primary cause of visual impairment worldwide. As with AMD, diabetes mellitus may be associated with ophthalmoscopically nonvisible neurovascular damage that progresses before the first clinical signs of diabetic retinopathy appear.⁹

Glaucoma

Most practices are resource-intensive with respect to the structural and functional evaluation of this disease. However, spatial contrast sensitivity also declines in different types and stages of glaucoma. A recent review discussed the role of CSF in the pathogenesis of glaucoma and its practical application in clinical practice.¹⁰

Neurodegeneration

Visual acuity is the ability to resolve the details of a stimulus and is affected by ophthalmic factors, including retinal deficits, as well as thalamic and cortical disease. Visual deficits are common in both Alzheimer's disease and Parkinson's. For example, contrast sensitivity, as measured using frequency-doubling technology, has been shown to be impaired in prodromal and mild

clinical Alzheimer's disease, and linked to future risk of dementia. Such patients show thinning of retinal layers, including the retinal nerve fiber layer, and loss of retinal ganglion cells.¹¹ All of these structural retinal changes can disrupt the CSF. Loss of contrast sensitivity is even associated with the presence of cerebral amyloid and tau deposition, and some researchers suggest "visual contrast sensitivity is a potential novel, inexpensive, and easy-to-administer biomarker for Alzheimer's disease-related pathology in older adults at risk for cognitive decline."¹²

Alterations in visual function from retinal thinning, as well as higher cortical brain regions, have also been found in Parkinson's disease, with some aspects of visuo-perceptual processing worsening with disease progression. There is also emerging data showing impaired pentagon copying as one of the earliest cognitive deficits in Parkinson's disease.¹³

Conclusion

CSF measurement, particularly in the presence of stress (low light/high glare) is the single-best method for assessing vision under real-life stressed conditions. The Stereo Optical FVA, with its versatile ability to quickly measure the CSF at one or several spatial frequencies under controlled conditions of mesopic, as well as photopic illumination and with and without glare, is a practice necessity. Image simulation with the EyeView software denotes clinical visual dysfunction and remains the benchmark—among an array of other



The Stereo Optical FVA, with its versatile ability to quickly measure CSF at one or several spatial frequencies under controlled conditions, is a practice necessity.

important but one-dimensional vision assessment technologies. The ability to supply rich granular data on the visual system is finally moving beyond the halls of research. ■

REFERENCES

1. ASHA. The audiogram. Available at: www.asha.org/public/hearing/Audiogram/ Last accessed Sep 28, 2021.
2. García-Lázaro S, Ferrer-Blasco T, Madrid-Costa D, Albarrán-Diego C, Montés-Micó R. Visual performance of four simultaneous-image multifocal contact lenses under dim and glare conditions. *Eye Contact Lens*. 2015;41(1):19-24.
3. Packer M, Fine IH, Hoffman RS. Contrast sensitivity and measuring cataract outcomes. *Ophthalmol Clin North Am*. 2006;19(4):521-533.
4. Richer S, Cho J, Stiles W, et al. Retinal spectral domain optical coherence tomography in early atrophic age-related macular degeneration (AMD) and a new metric for objective evaluation of the efficacy of ocular nutrition. *Nutrients*. 2012;4(12):1812-1827.
5. Richer SP, Stiles W, Statkute L, et al. A placebo-controlled, double blind, randomized trial of lutein and antioxidant supplementation for the treatment of age-related macular degeneration: The Lutein Antioxidant Supplementation Trial. *Optometry*. 2004;75:216-230.
6. Richer SP, Stiles WR, Levin MR, et al. The zeaxanthin and visual function study in atrophic age-related macular degeneration (ZVF-FDA IND #78,973). *Optometry*. 2011;82:687-680.
7. Akuffo KO, Beatty S, Peto T, et al. The impact of supplemental antioxidants on visual function in nonadvanced age-related macular degeneration: a head-to-head randomized controlled trial. *Invest Ophthalmol Vis Sci*. 2017;58:5347-5360.
8. Richer S, Park D-W, Epstein R, Wrobel JS, Thomas C. Macular re-pigmentation enhances driving vision in elderly adult males with macular degeneration. *J Clin Exp Ophthalmology*. 2012;3(3):1-5.
9. Safi H, Safi S, Hafezi-Moghadam A, Ahmadi H. Early detection of diabetic retinopathy. *Surv Ophthalmol*. 2018;63(5):601-608.
10. Ichhpujani P, Thakur S, Spaeth GL. Contrast sensitivity and glaucoma. *J Glaucoma*. 2020;29(1):71-75.
11. Coppola G, Di Renzo A, Ziccardi L, et al. Optical coherence tomography in Alzheimer's disease: a meta-analysis. *PLoS One*. 2015;10(8):e0134750.
12. Risacher SL, WuDunn D, Tallman EF, et al. Visual contrast sensitivity is associated with the presence of cerebral amyloid and tau deposition. *Brain Commun*. 2020;2(1):fcaa019.
13. Weil RS, Schrag AE, Warren JD, et al. Visual dysfunction in Parkinson's disease. *Brain*. 2016;139(11):2827-2843.



STEREO OPTICAL